

**МЕДИЦИНА, ПЕДАГОГИКА И ТЕХНОЛОГИЯ:  
ТЕОРИЯ И ПРАКТИКА**

**Researchbib Impact factor: 13.14/2024**

**SJIF 2024 = 5.444**

**Том 3, Выпуск 03, Март**

**УДК 616-007-053.1**

**АНАТОМИЧЕСКИЕ ОСОБЕННОСТИ ТРАХЕАЛЬНОГО БРОНХА И  
ЧАСТИЧНЫЙ АНОМАЛЬНЫЙ ДРЕНАЖ ЛЕГОЧНЫХ ВЕН**

(клинический случай)

**Д.Я. Хожиев**, кандидат медицинских наук, доцент, заведующий кафедрой анатомии и клинической анатомии Термезского филиала Ташкентской медицинской академии, Узбекистан

**Т.В. Татун**, магистр педагогических наук, ассистент кафедры нормальной анатомии Гродненского Государственного медицинского университета, Беларусь

**С. В. Аплевич**, врач, заведующий кабинетом рентгеновской компьютерной диагностики УЗ «Гродненская университетская клиника», Беларусь

**К. П. Астапенко**, врач кабинета рентгеновской компьютерной диагностики УЗ «Гродненская университетская клиника», Беларусь

**Аннотация:** Представлен клинический случай наличия добавочного бронха, отходящего из латеральной стенки трахеи, направленного к верхней доле легкого и участвующего в ее вентиляции. Установлено наличие частичного аномального дренажа легочных вен, дефект межпредсердной перегородки и гипоплазией правой подключичной вены. Рассмотрены рентгенологические особенности строения бронхиального дерева.

**Ключевые слова:** бронхиальное дерево, врожденная аномалия трахеи, трахеальный бронх, компьютерная томография, мультипланарные реконструкции КТ-изображений.

**УДК 616-007-053.1**

**ANATOMICAL FEATURES OF THE TRACHEAL BRONCHUS AND  
PARTIAL ANOMALOUS DRAINAGE OF THE PULMONARY VEINS: A**

Case Report

Khojiev DY<sup>1</sup> , Tatun TV<sup>2</sup> , Astapenka KP<sup>3</sup> , Aplevich SV<sup>4</sup>

# МЕДИЦИНА, ПЕДАГОГИКА И ТЕХНОЛОГИЯ: ТЕОРИЯ И ПРАКТИКА

Researchbib Impact factor: 13.14/2024

SJIF 2024 = 5.444

Том 3, Выпуск 03, Март

1 Department of Anatomy and clinical anatomy, Termez branch of the Tashkent  
Medical  
Academy, Uzbekistan

2 Department of Normal Anatomy, Grodno State Medical University, Belarus

3,4 Department of X-ray computer diagnostics, Grodno University Clinic, Belarus

Corresponding author: Khojiev DY, Associate Professor, 132000, Termiz city,  
Islam Karimov

street 64 – House, e-mail dkhojiev@gmail.com

**Abstract:** A clinical case of an anomaly in the development of the bronchial tree is described. A case is characterized by the presence of an additional bronchial branch, directed to the upper lobe of the lung and participating in its ventilation, and associated with a partial anomalous pulmonary venous drainage, with an atrial septal defect and hypoplasia of the right subclavian vein. Morphometric, topographic, and X-ray anatomical characteristics of the bronchial tree and lung parenchyma were established.

**Keywords:** bronchial tree, congenital tracheal anomaly, tracheal bronchus, partial anomalous pulmonary venous drainage computed tomography, multiplanar reconstructions of CT images.

## Introduction

Tracheal bronchus is a rare congenital anomaly of the bronchial tree, occurring in 1% of the world population, characterized by the presence of a bronchial branch extending from the lateral wall of the trachea, directed to the upper lobe of the lung and participating in its ventilation. Usually, the accessory bronchial branch is located on the right side of the trachea, at the level of the carina or 2 cm above it, but in other cases, tracheal bronchi can arise from the cricoid cartilage [2].

The tracheal bronchus in most cases is located on the border of the middle and distal thirds of the right side wall of the trachea, is more common in males and may be associated with stenosis of the right main bronchus [3].

In numerous studies conducted among children, the tracheal bronchus was present in 0.9–3%, in most cases arising from the right side wall. The prevalence of the right-sided accessory bronchus of the trachea ranged from 0.1 to 2%, and the prevalence of the left-sided bronchus was from 0.3 to 1% [6].

# МЕДИЦИНА, ПЕДАГОГИКА И ТЕХНОЛОГИЯ: ТЕОРИЯ И ПРАКТИКА

Researchbib Impact factor: 13.14/2024

SJIF 2024 = 5.444

Том 3, Выпуск 03, Март

The reasons for the development of the tracheal bronchus can be local disorders of morphogenesis, the result of the reposition of a previously developed bronchus, or combined with various dysontogenesis. Some researchers argue that this anomaly may be associated with other congenital anomalies such as Down syndrome, tracheoesophageal fistulas, esophageal, larynx, and duodenal atresia, spinal fusion defects, congenital heart defects, and pulmonary hypoplasia [6]. In other cases, a rare congenital anomaly of the bronchial tree can be associated with pathologies of congenital heart diseases (valvular heart disease, tetralogy of Fallot, and aortic coarctation) stenosis of the bilateral pulmonary arteries, stenosis or hypoplasia of the main bronchus, anomalous pulmonary venous connection, stenosis of the trachea [7].

There are several classifications of this rare pathological condition. According to one classification, there are three types of anatomical location of the tracheal bronchi: type I - the tracheal bronchus is more than 2 cm away from the the carina and there is a distal narrowing of the trachea; type II - the tracheal bronchus is more than 2 cm from the the carina, but there is no distal narrowing of the trachea; type III - the tracheal bronchus is 2 cm below the level of the the carina [4].

According to another classification, the tracheal bronchus is divided into three types: type I - the tracheal bronchus is a bronchial diverticulum and its diameter is almost equal to the diameter of the trachea; located above the carina (the bifurcation of the trachea) ; type II - the bronchus begins above the carina (the bifurcation of the trachea) and ventilates the upper lobe of the lung; and type III - the tracheal bronchus is fully developed and located at the level the carina (the bifurcation of the trachea) [1,6].

In most cases, the tracheal bronchus is discovered by chance, more often they are asymptomatic, but sometimes it can be manifested by cough, chronic bronchitis, recurrent right-sided pneumonia.

Partial anomalous pulmonary venous drainage is characterized by the absence of connection of one or more veins with the left atrium and drainage of the pulmonary veins into the right atrium or vena cava, which accounts for 0.3% of all congenital heart defects. In 25% of cases, it is associated with an atrial or ventricular septal defect and anomalies in the structure of the trachea and bronchial tree.

# МЕДИЦИНА, ПЕДАГОГИКА И ТЕХНОЛОГИЯ: ТЕОРИЯ И ПРАКТИКА

Researchbib Impact factor: 13.14/2024

SJIF 2024 = 5.444

Том 3, Выпуск 03, Март

## Case presentation

We observed a 40-year-old man, who underwent multispiral computed tomography (MSCT) of the thoracic cavity in 2023 at the University Clinic. The CT images looked as follows: an accessory (tracheal) bronchus was visualized at the level of the fifth thoracic vertebra, 22 mm above the level of the carina (tracheal bifurcation) [Figure 1: computed tomography images]. It independently departed from the lateral wall of the trachea on the right, went to the upper lobe of the right lung and participated in its ventilation. Its diameter was 8 mm, length 25 - mm. In the parenchyma of the upper lobe of the right lung, it was divided into two branches: *the anterior branch*, 16 mm long and 3 mm in diameter, which divided dichotomously and occupied the parenchyma of the anterior-apical segment of the lung parenchyma, and *the posterior branch*, 10 mm long and 5 mm in diameter, which also divided dichotomously and occupied the parenchyma of the posterior-apical segment of the lung parenchyma.

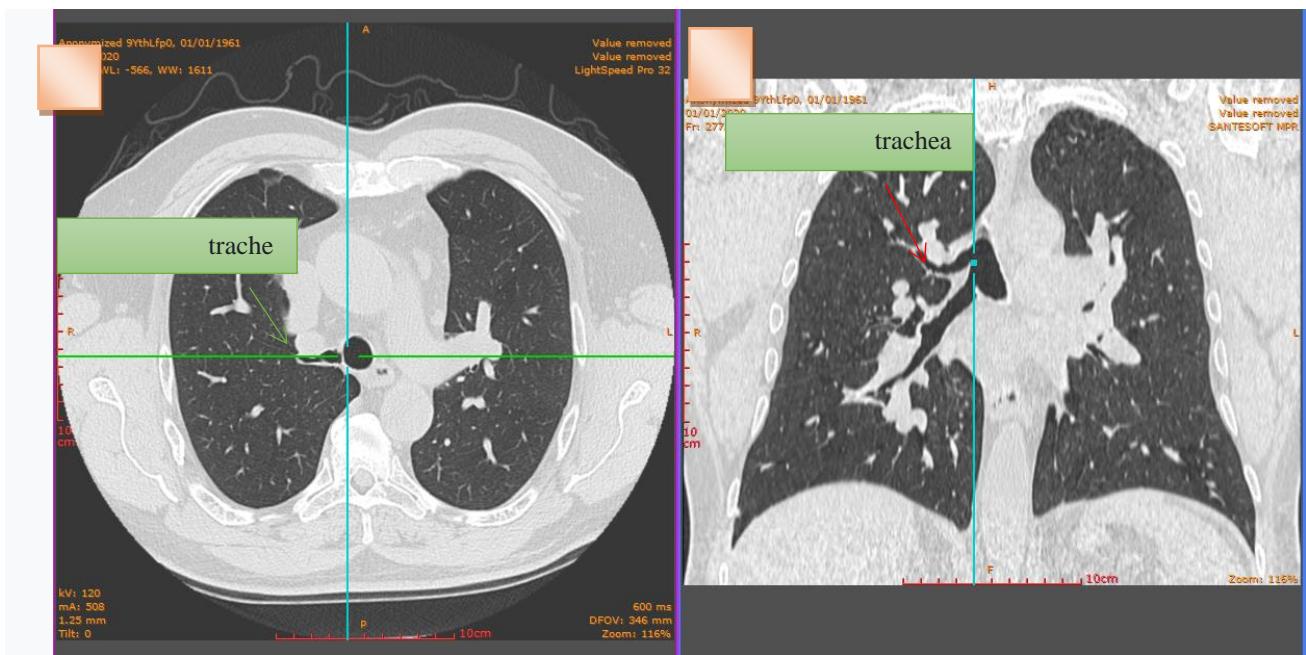


Figure 1 - an accessory (tracheal) bronchus.

CT scan: a - an axial chest CT image with lung window, b - coronal chest CT image with lung window.

The bronchial tree looked like this: two main bronchi departed from the trachea, the right one was narrowed, its diameter was 8 mm and 31 mm long, the left main

# МЕДИЦИНА, ПЕДАГОГИКА И ТЕХНОЛОГИЯ: ТЕОРИЯ И ПРАКТИКА

Researchbib Impact factor: 13.14/2024

SJIF 2024 = 5.444

Том 3, Выпуск 03, Март

bronchus was wider with a diameter of 11 mm and a length of 48 mm. [Figure 2: computed tomography images].

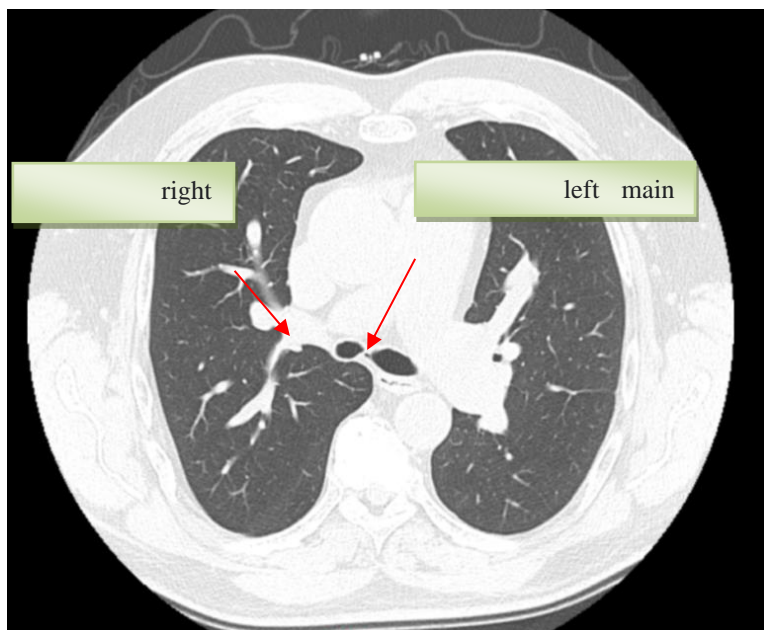


Figure 2. CT scan: - an axial chest CT image with lung window.

At the at the hilum of the right lung, the right main bronchus was divided into three lobar bronchi: upper, middle and lower, while the oblique interlobar fissure of the right lung was within normal, and the horizontal interlobar fissure was incomplete, dividing the lung parenchyma into 1/3 of the anterior and lateral sections of the lung. There was a change in the structure and division of superior lobar bronchus. The upper right lobar bronchus was 4 mm wide, located lower than usual at the level of the middle third of the body of the seventh thoracic vertebra and divided only into two segmental bronchi: anterior and posterior, corresponded to normal third-order segmental bronchi.

According to the anatomical structure of the bronchial tree, the right upper lobe bronchus is divided into three segmental bronchi: apical, posterior and anterior, located in the upper lobe of the lung parenchyma. In our case, the accessory tracheal bronchus was defined as an apical segmental bronchus of the third order, which was directed to the upper lobe of the right lung in the apical segment. The pulmonary parenchyma was without additional formations and inflammatory changes.

# МЕДИЦИНА, ПЕДАГОГИКА И ТЕХНОЛОГИЯ: ТЕОРИЯ И ПРАКТИКА

Researchbib Impact factor: 13.14/2024

SJIF 2024 = 5.444

Том 3, Выпуск 03, Март

The clinical case was associated with partial congenital anomalous drainage of the right upper and lower pulmonary veins into the superior vena cava and an operated atrial septal defect.

The anatomical features of the blood supply of the segments of the anomalous tracheal bronchus were as follows: the right pulmonary veins merged into segmental trunks with diameters of 12 mm (anterior) and 8 mm (posterior), and then merged into a common trunk with a cross-section of 17 mm. Blood drained into the superior vena cava instead of the left atrium, which indicates a false "scimitar" syndrome (partial anomalous drainage of the pulmonary veins). Mixing of blood occurs at the site of drainage of the right pulmonary veins and the superior vena cava. Oxygenated blood, entering the lumen of the superior vena cava, with a mixture of deoxygenated blood, flows into the right atrium, creating difficulty in the work of the heart and pulmonary vessels in the form of hypertension and hypoxia of the internal organs.

Hypoplasia of the right subclavian vein was detected: the diameter was narrowed to 3 mm in the area 10 mm distal to the intersection of the first rib and was located 10 mm before it entered the right brachiocephalic vein.

## Conclusion

As a result of the study, an anatomical picture of the structure of the bronchial tree with the presence of the right tracheal bronchus was revealed. This rare congenital anomaly was associated with stenosis of the right main bronchus, hypoplasia of the right subclavian vein, incomplete right horizontal interlobar fissure, corresponded to type II (the bronchus began 22 mm above the bifurcation and ventilated the upper lobe of the lung), partial congenital anomalous drainage of the right upper and lower pulmonary veins into the superior vena cava and an operated atrial septal defect. Such an anomaly was revealed for the first time in the University Clinic [5]. The case described expands and complements the understanding of the morphometric, topographic and radiological characteristics of a rare congenital pathology of the bronchial tree.

## Conflict of interest

None.

# МЕДИЦИНА, ПЕДАГОГИКА И ТЕХНОЛОГИЯ: ТЕОРИЯ И ПРАКТИКА

Researchbib Impact factor: 13.14/2024

SJIF 2024 = 5.444

Том 3, Выпуск 03, Март

## Acknowledgement

None.

## References

1. Conacher ID. Implications of tracheal bronchus for adult anaesthetic practice // Br J Anaesth. – 2000. – Vol. 85. – P. 317-337.
2. DelPizzo KR, Tracheal bronchus in a 10-month-old patient for thoracoscopic resection of congenital cystic adenomatoid malformation / DelPizzo KR, Joffe DC, Finkel JC. // J PediatrAnesth. – 2006. – Vol. 16. – P. 997-1005.
3. Doolittle AM, Tracheal bronchus: classification, endoscopic analysis, and airway management / Doolittle AM, Mair EA // J. OtolaryngolHead Neck Surg. – 2002. – Vol. 3.– P.240-243.
4. Giral T, Ventilation unipulmonaire chez unepatientprésentantune trifurcation bronchique / Giral T, Marandon J-Y, Fischler M. // J. Ann FrAnesthRéanim. –2014. – Vol. 33.– P.272-276.
5. Khojiev DY, Morphological features of the small intestine: A Case Report / D. Y. Khojiev, T. V. Tatun, K. P. Astapenka, D. J. Khalimova // Journal of Advanced Zoology. – 2023. – Vol. 44 (S2). – P. 5379-83.
6. Lawrence DA, The wonderful world of the windpipe: a review of central airway anatomy and pathology / Lawrence DA, Branson B, Oliva I, Rubinowitz A. //J Canadian Association of Radiologists. – 2015. – Vol. 66.– P.30-43.