

MINIMALLY INVASIVE SURGICAL METHOD FOR FRACTURES OF THE PROXIMAL HUMERUS

A.P.ALIMOV, S.Y.YUSUPOV, S.K.HAKIMOV

Republican Specialized Scientific and Practical Medical Center of Traumatology and Orthopedics Ministry of Health of the Republic of Uzbekistan, Tashkent City.

Bukhara State Medical Institute, Bukhara City. Bukhara Branch of the Republican Scientific Center for Emergency Medical Aid, Bukhara City.

Purpose of work was improving treatment outcomes by developing an extramedullary minimally invasive method in fractures of the proximal portion of the humerus.

Materials of the scientific work is devoted to clinical data of 55 patients with multiple fragment fractures of the proximal portion of the humerus. The Neer (1970) classification was used to assess the severity of the injury and the condition of the bone fragments. Most patients fall into the category of surgical fracture of the humerus, of these, 8 (14.6%) were single-fragment fractures, 14 (25.3%) were double-fragmented, 15 (27.3%) were three-fragmented, and the remaining 18 (32.8%) were multi-fragmented fractures. All patients made surgery using new operative technique using an extramedullary minimally invasive method with Ilizarov apparatus and atraumatic threads in different directions through the rotator cuff muscles of the shoulder attached to the bone fragments for the ideal repositioning of the bone fragments.

Results. Out of a total of 55 patients, 47 (85.4%) had a total score above 90 and were rated as good outcomes. Satisfactory results were obtained in 5 (9.2%) patients with the total score about 80 - 89. The satisfactory results were explained by the limitation of the amplitude of movement up to 10 degrees in the shoulder joint. In the remaining 3 (5.4%) patients, an unsatisfactory result was observed, the total score was less than 80, i.e., the presence of pain syndrome in the shoulder joint in these cases, limitation of range of motion to 15 degrees, and was explained by the presence of signs of osteoarthritis in the control X-ray image. After the surgery, all patients underwent shoulder rotator cuff restorative treatments for the prevention of

"impingement syndrome", on the 21-25th day after the surgery, therapeutic physical exercises for the shoulder joint were started.

Conclusions.

Discussions on the choice of treatment for fractures of the proximal part of the humerus are growing. The proposed method of minimally invasive osteosynthesis in fractures of the proximal part of the humerus allows for less traumatic reposition of bone fragments, stable fixation of bone fragments. The proposed method of minimally invasive osteosynthesis allowed to increase the share of good and satisfactory results to 94.5%, as well as to improve the quality of life of patients.

KEYWORDS: humerus, proximal humerus fractures, osteosynthesis, plate.

СОВРЕМЕННАЯ ТЕХНИКА ОСТЕОСИНТЕЗА ПРИ ПРОКСИМАЛЬНЫХ ПЕРЕЛОМАХ ПЛЕЧЕВОЙ КОСТИ

А.П. Алимов, С.Ю. Юсупов, Ш.К. Хакимов, А.Ш. Муминов, Ш.Ш.Ахмедов

Цель исследования. Улучшение результатов лечения путем разработки миниинвазивной оперативной техники при переломах проксимального отдела плечевой кости.

К материалам исследования включены 40 пациентов с переломами проксимального отдела плечевой кости. У 15 больных отмечалось варусное смещение костных отломков. Среди больных 15 составили мужчины и 25 женщины. Давность травмы в среднем $5,8 \pm 1,8$ сутки. В клинике разработана техника экстрамедуллярного остеосинтеза с использованием миниинвазивной пластины и применением наружного дистракционного аппарата с целью минимизации травматичности оперативного вмешательства и активно применена больным с переломами проксимального отдела плечевой кости.

Результаты. У больных с переломами проксимального отдела плечевой кости результаты лечения оценивали с использованием 100 балльной шкалой Neer C.S. и соответственно среди всех 40 пациентов у 37 (92,5%) отмечены хорошие, у 2 (5%) удовлетворительные и у остального 1 (2,5%) больных неудовлетворительные послеоперационные результаты, что последние были связаны с наличием болевого синдрома, ограничения амплитуды движения до

15 градусов и признаков артроза в плечевом суставе на контрольной рентгенограмме.

Выводы.

1. предложенная миниинвазивная оперативная техника при переломах проксимального отдела плечевой кости позволяла провести малотравматичной репозиции и стабильной фиксации костных отломков.

2. предложенная миниинвазивная оперативная техника способствует повышению доли лучших результатов до 97,5%, а также улучшению качества жизни больных.

Ключевые слова: плечо, проксимальный, миниинвазивный, остеосинтез.

Relevance of the subject

Fractures of the proximal part of the humerus account for 5% of all injuries of the human musculoskeletal system [1, 6]. The incidence of this type of injury is 50 per 100,000 population per year, and at the same time, the statistical indicator has increased several times over the last 30 years [2, 4]. Fractures of this type often occur in elderly patients, often on the background of osteoporosis, and do not require high-tension injury based on trauma mechanism [3, 5].

In injuries of the proximal part of the humerus, the mechanism of interconnection of the shoulder girdle is disrupted, making it difficult to restore the functional activity of the shoulder joint [7, 8]. As a result of scientific research in addition to restoring the anatomical axis and length of the shoulder in fractures of the proximal part of the shoulder, the idea is being promoted that it is necessary to restore the normal anatomical junction of the rotators of the proximal part of the shoulder, otherwise, it will not be possible to restore the full functional capacity of the shoulder joint without this activity [9, 10].

One of the most common consequences of fractures of the proximal part of the humerus is that the frequency of fractures of the proximal part of the shoulder is the same after conservative and surgical procedures - 11% [3, 4, 7, 8, 11], this occurs as a result of the repositioning of initially incomplete bone fragments, as well as the observation of secondary displacement in the instability of fixation. These types of fractures result in limited range of motion in the shoulder joint and subacromial impingement syndrome, as a result, it has a significant impact on patients' pain

syndrome discomfort for many years and on patients' lifestyles [12, 13, 14, 15, 28, 29].

The development of new less traumatic methods of osteosynthesis in proximal epimetaphyseal fractures of the humerus, which not only provide reliable fixation of bone fragments, but also fully restore its anatomy, remains one of the urgent tasks of modern traumatology. In recent years, osteosynthesis using specialized implants [1, 16, 17, 18, 26, 27, 30] in a closed manner using low-injury superficial bone plates has become increasingly competitive with blocking intramedullary osteosynthesis [19, 20, 21, 22, 23, 24, 25, 31]. An analysis of the available literature suggests that data on the use of extramedullary osteosynthesis techniques for closed repositioning of bone fragments and achievement of adequate stability in proximal fractures of the humerus are insufficient.

The purpose of the research. Improving treatment outcomes by developing an extramedullary minimally invasive method in fractures of the proximal portion of the humerus.

Materials and verification methods.

This research has been conducted on the clinical bases of the Republican Specialized Scientific-Practical Medical Center for Traumatology and Orthopedics and the Bukhara branch of the Republican Scientific Center for Emergency Care. A total of 55 patients with multiple fragment fractures of the proximal portion of the humerus have been recruited for the research, in 15 of these, bone fragments have been found to have shifted in the varus position (Table 1).

Patients have been divided by sex, and 25 of them were male and 30 were female. The average duration of injury was 4.8 ± 1.2 days (3 to 7 days). Surgical procedures were offered to each patient selected for the research work. In order to reduce the invasiveness of surgical procedures in fractures of the proximal part of the shoulder a method of extramedullary osteosynthesis of bone fragments using easy, minimally invasive external repositioning apparatus to achieve adequate repositioning and using minimally invasive plate has been developed in our clinic.

All patients underwent standard clinical, radiological examination methods before surgery. X-ray examination has been performed in standard anterior, lateral, and axial projections. Due to multi-fragmentary fractures observed in patients, the

Neer (1970) classification was used to assess the severity of the injury and the condition of the bone fragments (Table 1).

Table 1

Segmentation of patients with fractures of the proximal humerus according to the Neer classification

	Single-fragment	Double-fragmented	Three-fragmented	Multi-fragmented
Fracture of the humerus through anatomical neck	3 (5,4%)	3 (5,4%)	-	-
Surgical fracture of the humerus	5 (9,2%)	8 (14,5%)	12 (21,9%)	18 (32,8%)
Large ridge fracture	-	-	-	-
Small ridge fracture	-	-	-	-
Fractures and luxations	Anterior	-	3 (5,4%)	-
	Posterior	-	-	3 (5,4%)

As can be seen from Table 1, most patients fall into the category of surgical fracture of the humerus, of these, 8 (14.6%) were single-fragment fractures, 14 (25.3%) were double-fragmented, 15 (27.3%) were three-fragmented, and the remaining 18 (32.8%) were multi-fragmented fractures. Fracture of the humerus through anatomical neck was detected in 6 (10.8%) patients, of these, 3 (5.4%) were single-fragmented fractures and the remaining 3 (5.4%) were double-fragmented fractures. In 6 (10.8%) patients, a proximal fracture of the humerus was observed and two- and three-fragment fractures were detected.

The essence of the minimally invasive surgical treatment method developed in the clinic is that a clinically developed external distraction device was used to reposition bone fragments in patients with a fractured proximal humerus and osteosynthesis was performed with a minimally invasive blocking plate through a small-sized wound incision.

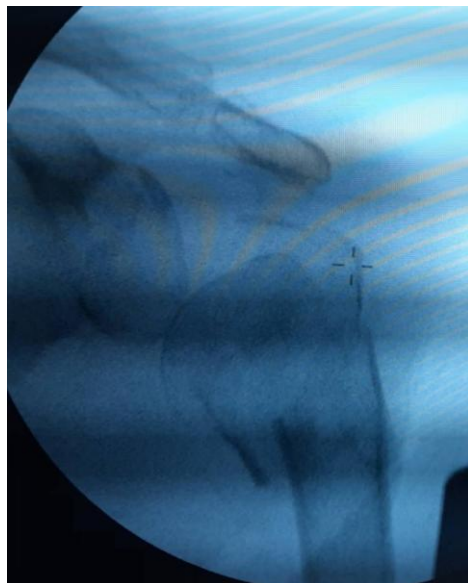
Clinical and radiological results in patients after treatment have been evaluated at 1, 3, 5, 7 months after surgery. The complaints of patients were taken into account, the amplitude of active and passive movements in the shoulder and elbow joints were

measured and evaluated using Constant scale [5]. On the basis of a stepwise X-ray examination, the radiological dynamics of the fracture site closure, the state of fixation, and secondary displacements, if any, have been studied.

The surgical procedure technique is described in the following clinical example.

Patient S., 62 years of age, was admitted to the department of "emergency traumatology" of Bukhara branch of the Republican Scientific Center for Emergency Care 3 hours after the injury at home (first aid was provided at the place of residence). During the examination, the patient complained of pain, swelling in the area of the shoulder joint. The shoulder joint was deformed, and active and passive movements were severely limited. X-ray examination revealed a multi-fragmentary fracture of the proximal part of the humerus (Figure 1a).

Figure 1a. Patient S., 62 years of age. Anterior-posterior projection x-ray of the

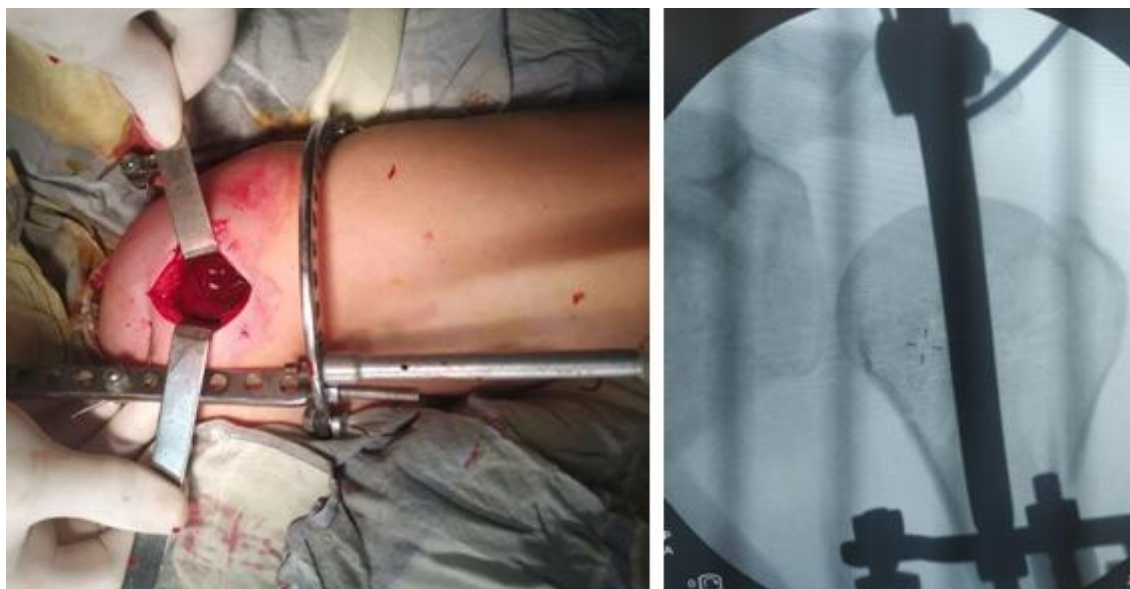


shoulder joint: a multi-fragmentary fracture of the proximal portion of the humerus and the valgus position of the bone fragments has been detected.

Surgical treatment was recommended after the patient received the necessary additional conservative treatment in the department.


Surgery: The patient lying on his back, under general intravenous anesthesia and X-ray television monitoring a multi-fragment fracture of the proximal portion of the humerus was confirmed. The shoulder was moved 30–35 ° away from the body, and in the external rotation position, one proximal spit of the distractor was passed through the acromion. The distal part of the humerus was held at the intersection of 2 Ilizarov wires on the ridges and fixed to the distal ring of the distractor. Distraction was given to the external apparatus. The position of the bone fragments is relatively satisfactory when viewed on an X-ray television device (Figures 1b, c).

Figure 1b. – distraction to the fractured area using an external distraction apparatus to the shoulder joint **c.** - anterior posterior projection x-ray of the shoulder



joint: given distraction by external apparatus and the presence of bone fragments is satisfactory.

A skin incision of 4.0 cm in size was made on the outer surface of the shoulder joint, the wound layer was opened, hemostasis. Because the proximal portion of the humerus in the revision contained multiple fragmented fractures, atraumatic sutures were performed from the junction of the shoulder rotator cuff muscles attached to the bone fragments and ideally repositioned (Figures 1d, e).



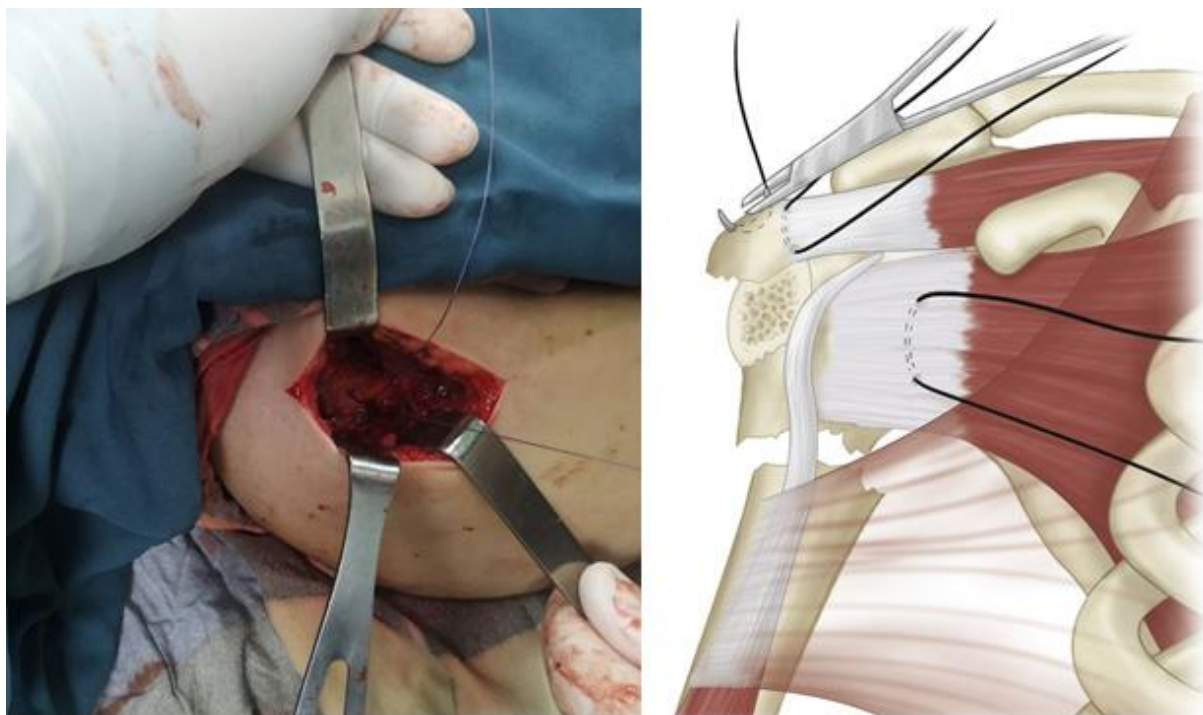


Figure 1d. d – atraumatic threads were passed in different directions through the rotator cuff muscles of the shoulder attached to the bone fragments and the ideal repositioning of the bone fragments was achieved., e – schematic view.

Under the X-ray television device, a blocking plate was placed along the outer surface of the humerus and tightened using screws (Fig. 1f).

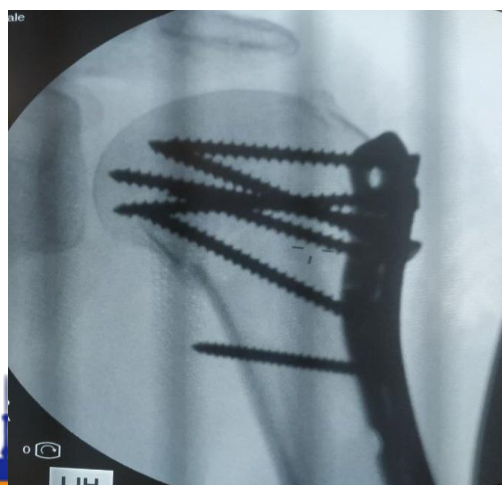

Figure 1f. A blocking plate is mounted along the outer surface of the humerus and secured using screws.

The low trauma of the practice is due to the small size of the practice wound and the orientation of the plate along the bone surface, and is explained by the prevention of injury to the nerve axillary innervating the musculus deltoideus.

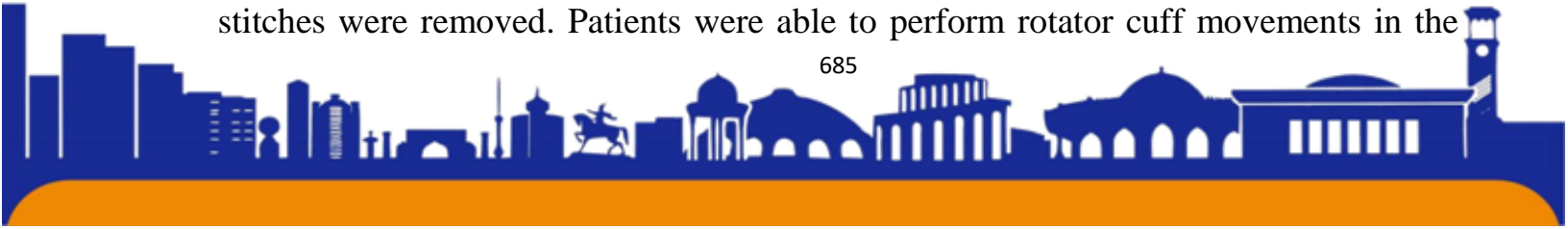
The external distractor apparatus was dismantled after we were satisfied that the placement of bone fragments in the X-ray television device was satisfactory. The operation wound was sutured layer by layer. The duration of the surgical procedure was 45 minutes (Fig. 1g).

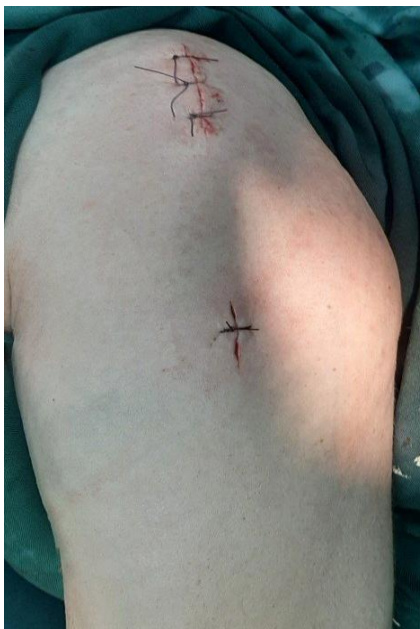

Figure 1g. The operation wound sutured.

The surgical procedure proposed by us was sent to the Republican Private Property Agency for patenting.

The postoperative period passed without complications. Patients walk in a bandage for 15 days, passive movements in the shoulder joint were allowed after the stitches were removed. Patients were able to perform rotator cuff movements in the



shoulder joint one month after surgery and complete painless movements two months later.

Analysis of the results of surgical procedures.

The method proposed by us allowed to restore the anatomy of the proximal part of the humerus in all 55 patients and to eliminate varus deformity. The low invasiveness of the operation ensured the restoration of the functional state of the shoulder joint.

Postoperative long-term results in patients with proximal fracture of the shoulder have been rated on Neer C.S. scale [24], that is, the main symptoms are pain in the shoulder joint and loss of function (active removal and rotation of the arm) [25]. Neer C.S. scale is a 100 points scale and evaluated using the following criteria: pain syndrome in the fracture area - 0 to 35 points; upper limb activity - 0 to 30 points; amplitude of movement of the shoulder joint - 0 to 25 points; the presence of anatomical changes in the proximal part of the humerus - 0 to 10 points.

Good results were defined when the sum of the scores ranged from 90 to 100 points. Satisfactory from 80 to 89 points and poor unsatisfactory results from 79

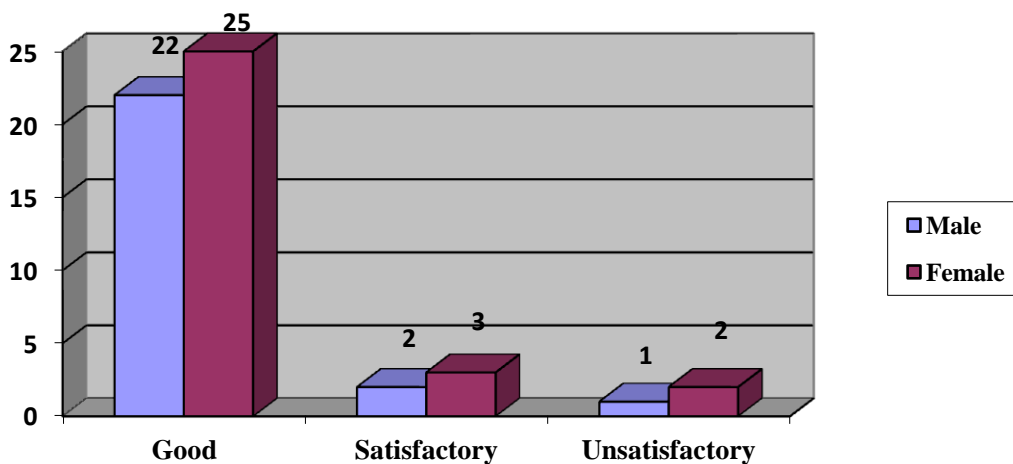


Diagram 1 - evaluation of postoperative long-term results of patients with fractures of the proximal part of the humerus according to Neer C. S. scale

According to Diagram 1, out of a total of 55 patients, 47 (85.4%) had a total score above 90 and were rated as good outcomes. Satisfactory results were obtained in 5 (9.2%) patients and the total score was 80 - 89. The satisfaction of the results in

these patients was explained by the limitation of the amplitude of movement up to 10 degrees in the shoulder joint. In the remaining 3 (5.4%) patients, an unsatisfactory result was observed, the total score was less than 80, i.e., the presence of pain syndrome in the shoulder joint in these cases, limitation of range of motion to 15 degrees, and was explained by the presence of signs of osteoarthritis in the control X-ray image. After the surgery, all patients underwent shoulder rotator cuff restorative treatments for the prevention of "impingement syndrome", on the 21-25th day after the surgery, therapeutic physical exercises for the shoulder joint were started.

Discussion

Recently, the similarity of the results of intraosseous and superficial osteosynthesis in proximal fractures of the humerus has been emphasized by many scientists. [1, 9, 16].

Modern implants (superficial and intramedullary implants) provide fixation of bone fragments using a large number of screws with angular stability in different planes. However, the misalignment of the varus deformations and the uncertainty of fixation are 20% [3, 15].

There is also the possibility of varus collapse when using intramedullary pins. Polarus nails have been used by B.M. Nolan and co-authors in 18 patients using traditional methods of fixation, in 17 of them a decrease in the cervical-diaphyseal angle by an average of 11 ° and in 9 patients a cervical-diaphyseal angle with a value of less than 120 ° have been revealed, that is, a misalignment was found in the varus deformity [27, 28, 30, 30, 31].

Scientists have proposed many types of external fixation osteosynthesis that are simple and quick to install. However, in these types of osteosynthesis, the proximal portion of the humerus is difficult to mobilize, reposition, and fixate. Therefore, the mobilization of the pieces is almost impossible to achieve without opening the broken area and separating it in the open position. Moreover, in many cases, especially in multi-fragment fractures, it is not possible to correct the rotational displacements of the bone fragments. The distractor offered by us easily solved this problem, i.e. the distractor has the ability to rotate the distal ring of the apparatus at any angle.

Advantages of the proposed surgical procedure method:

1. the low trauma of the practice is due to the small size of the surgical incision and the absence of the need for wide opening of the tissue;

2. firm fixation of bone fragments;
3. the possibility of restoring the normal anatomy of the proximal part of the humerus.
4. early activation of patients and improvement of active quality of life;

Conclusions

1. Discussions on the choice of treatment for fractures of the proximal part of the humerus are growing.
2. The proposed method of minimally invasive osteosynthesis in fractures of the proximal part of the humerus allows for less traumatic reposition of bone fragments, stable fixation of bone fragments.
3. The proposed method of minimally invasive osteosynthesis allowed to increase the share of good and satisfactory results to 94.5%, as well as to improve the quality of life of patients.

References:

1. Keener J. D., Parsons B. O., Flatow E. L., Rogers K., Williams G. R., Galatz L. M. Outcomes after percutaneous reduction and fixation of proximal humeral fractures. *J. Shoulder Elbow Surg*, 2007; 6: 330–338.
2. Loskutov A. E., et al. Differencirovannye podhody k operativnomu lecheniyu bol'nyh s povrezhdeniyami proksimal'nogo otdela plechevoi kosti [Different approaches to surgical treatment of patients with damages of proximal humerus]. *Ortopediya, traumatologiya i protezirovanie [Orthopaedics, traumatology and prosthetics]*, 2007; 1: 33–38.
3. C.M., et al. Modern perspectives of open reduction and plate fixation of proximal humerus fractures. *J.Orthop. Trauma*, 2011; 25(10): 618-629.
4. Sun J.C., et al. Treatment of three- and four-part proximal humeral fractures with locking proximal humerus plate. *Eur. J. Orthop. Surg. Traumatol*, 2013; 23(6): 699-704.
5. Rothstock S., et al. Biomechanical evaluation of two intramedullary nailing techniques with different locking options in a three-part fracture proximal humerus model. *Clin. Biomech. Bristol, Avon*, 2012; 27(7): 686-691.

6. Den Hartog D, et al. Primary shoulder arthroplasty versus conservative treatment for comminuted proximal humeral fractures: a systematic literature review. *Open Orthop. J*, 2010; 4: 87-92.
7. Brunner A., et al. Minimally invasive percutaneous plating of proximal humeral shaft fractures with the Proximal Humerus Internal Locking System (PHILOS). *J. Shoulder Elbow Surg*, 2012; 21(8): 1056-1063.
8. Dilisio MF, et al. Intramedullary nailing of the proximal humerus: evolution, technique, and results. *J Shoulder Elbow Surg*, 2016; 25(5): 130-e138. doi: 10.1016/j.jse.2015.11.016.
9. Zhu Y, Lu Y, Shen J, Zhang J, Jiang C. Locking intramedullary nails and locking plates in the treatment of two-part proximal humeral surgical neck fractures: a prospective randomized trial with a minimum of three years of follow-up. *J Bone Joint Surg Am*, 2011; 93(2): 159-168. doi:10.2106/JBJS.J.00155.
10. Gavaskar AS, Karthik BB, Tummala NC, Srinivasan P, Gopalan H. Second generation locked plating for complex proximal humerus fractures in very elderly patients. *Injury*, 2016; 47(11): 2534-2538. doi:10.1016/j.injury.2016.08.010.
11. Wong J, Newman JM, Gruson KI. Outcomes of intramedullary nailing for acute proximal humerus fractures: a systematic review. *J Orthop Traumatol*, 2016; 17: 113–122.
12. Magovern B, et al. Percutaneous fixation of proximal humerus fractures. *Orthop Clin North Am*, 2008; 39: 405–416.
13. Yang K. H. Helical plate fixation for treatment of comminuted fractures of the proximal and middle one-third of the humerus // *Injury*, 2005; 36: 75–80.
14. Martin C., Guillen M., Lopez G. Treatment of 2- and 3-part fractures of the proximal humerus using external fixation: a retrospective evaluation of 62 patients // *Acta Orthop*, 2006; 77: 275–278.
15. Minayev A.N., Gorodnichenko A.I., Uskov O.N. The transosseous osteosynthesis by proximal metaepiphyseal fractures of humerus in elderly patients. *Khirurgiya*, 2010; (1): 50–53. (In Russian).
16. Gurkin B.E., et al. Basis for choice of treatment of patients with fracture of the proximal humeral. *Kubanskiy nauchnyy meditsinskiy vestnik*, 2015; (2): 49–56. (In Russian).

17. Slobodskoy A.B., et al. Morphological changes in the head of the humerus in acute injury of the proximal humerus in elderly patients. In: Ilizarov readings: materials of the scientific and practical conference with international participation. Kurgan, 2011: 260–261. (In Russian).

18. Robinson B.C., et al. Classification and imaging of proximal humerus fractures. *Orthop Clin North Am*, 2008; 39(4): 393–403. DOI: 10.1016/j.ocl.2008.05.002.

19. Skoroglyadov A.V., et al. Possibility of Ultrasound Diagnosis for Visualization of Peripheral Nerves of and Forearm. *Vestnik travmatologii i ortopedii imeni NN Priorova*, 2008; (2): 64–69. (In Russian).

20. Mora Guix J.M., et al. Classification System for Proximal Humeral Fractures. *Clin Med Res*, 2009; 7(1–2): 32–44. DOI: 10.3121/cmr.2009.779.

21. Kogan PG, et al. [Treatment evolution of proximal humeral fractures (literature review)]. *Travmatologiya i ortopediya Rossii [Traumatology and Orthopaedics of Russia]*, 2013; (3): 154-161.

22. Murylev V, Imamkuliev a, Elizarov P, Korshev O, Kutuzov a. [Surgical treatment of extraarticular fractures of the proximal humerus]. *Vrach [Physician]*, 2014; (11): 10-13.

23. Iyengar JJ, Devcic Z, Sproul RC, feeley BT. Nonoperative treatment of proximal humerus fractures: a systematic review. *J Orthop Trauma*, 2011; 25(10): 612-617.

24. Buecking B., et al. Deltoid-split or Deltopectoral Approaches for the Displaced proximal humeral fractures? // *Clin. Orthop. Relat. Res*, 2014; 47: 1576-1585.

25. Boudard G., et al. Locking plate fixation versus antegrade nailing of 3- and 4-part proximal humerus fractures in patients without osteoporosis. Comparative retrospective study of 63 cases. *Orthop Traumatol Surg Res*, 2014; 100(8): 917–924. DOI: 10.1016/j.otsr.2014.09.021.

26. Lekic N., et al. Treatment of two-part proximal humerus fractures: intramedullary nail compared to locked plating. *HSS J*, 2012; 8(2): 86–91. DOI: 10.1007/s11420-012-9274-z.

27. Eldzarov P.E., et al. Surgical treatment of consequences of femoral fractures. *Khirurgiya*, 2010; (9): 47–52. (In Russian).
28. Minayev A.N., et al. The transosseous osteosynthesis by proximal metaepiphyseal fractures of humerus in elderly patients. *Khirurgiya*, 2010; (1): 50–53. (In Russian).
29. Mora Guix J.M., et al. Updated Classification System for Proximal Humeral Fractures. *Clin Med Res*, 2009; 7(1–2): 32–44. DOI: 10.3121/cmr.2009.779.
30. Duralde X.A., et al. The results of ORIF of displaced unstable proximal humeral fractures using a locking plate. *J Shoulder Elbow Surg*, 2010; 19(4): 480–488. DOI: 10.1016/j.jse.2009.08.008.
31. Pritchett J.W. Inferior subluxation of the humeral head after trauma or surgery. *J Shoulder Elbow Surg*, 1997; 6(4): 356–359. PMID: 9285875.