



MORPHOFUNCTIONAL CHARACTERISTICS OF THE SMALL INTESTINE DURING EXPERIMENTAL CHOLECYSTECTOMY AND ANTIHYPOXANT THERAPY IN ACUTE SMALL INTESTINAL OBSTRUCTION

Abduraimov Zafar Abduraimovich, Hidirov Ziyadulla Erkinovich

Assistant teachers of the Department of Human Anatomy of Samarkand State Medical University

Annotation. This article discusses the morphofunctional characteristics of the small intestine, cholecystectomy in the small intestine. It also provides information on antihypoxant therapy of the small intestine with examples.

Key words: pathogenesis, intestinal obstruction, necrosis small intestine, morphology, reamberin.

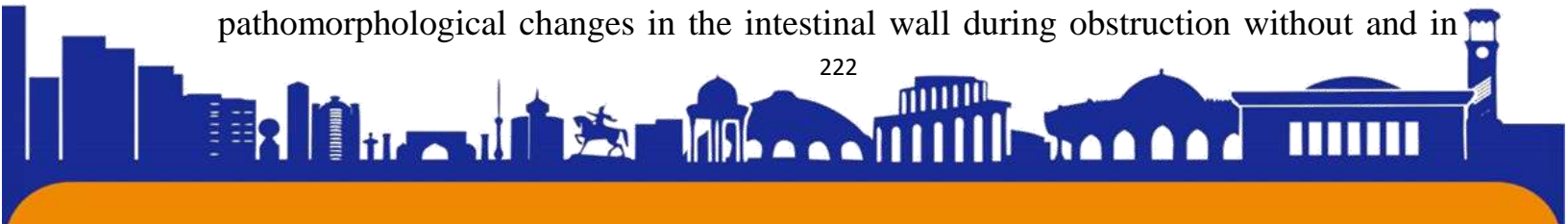
INTRODUCTION

The study of the etiology, pathogenesis, diagnosis and treatment of small intestinal obstruction in modern medicine is relevant. Despite the achievements of recent years, the mortality rate from this disease is 15-52%. In acute intestinal obstruction, multiple organ lesions occur, which are associated primarily with a violation of the barrier function of the intestinal wall. Most of the data on the structure of the intestinal wall during intestinal obstruction are presented by experimental studies. Data on the objectification of structural disorders that occur in the wall of the small intestine during acute intestinal obstruction and their correction in humans are scarce, which determined the need for this work.

Traditional cholecystostomy followed by mucoclasia of the gallbladder minimizes surgical and anesthetic risks in elderly and senile patients with acute calculous cholecystitis, and postoperative administration of Roncoleukin allows increasing the indicators of cellular immunity in this category of patients. At the same time, the effectiveness of Roncoleukin in relation to cellular indicators of local immunity of the nearby small intestine remains unstudied.

The goal is to study the state of the tissue structures of the wall of the small intestine in acute mechanical obstruction in humans and its correction in an experiment with a solution of reamberin.

To be able to collect material in the dynamics of an experiment when studying pathomorphological changes in the intestinal wall during obstruction without and in





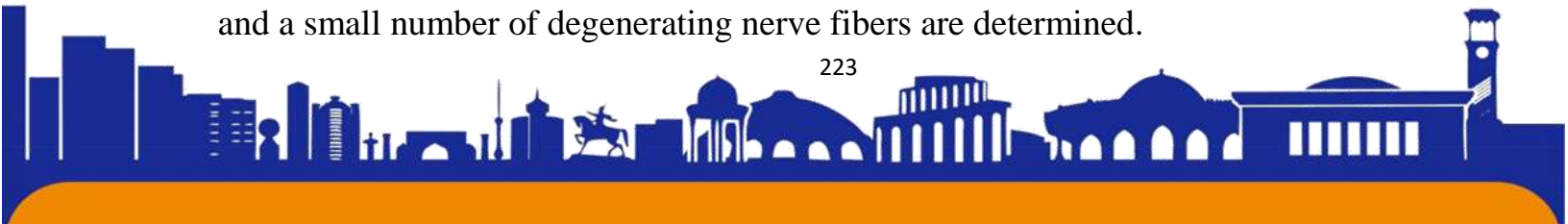combination with the developed method of using antioxidant and antihypoxic therapy, a “zipper” was sewn into the laparotomy wound for a predicted laparotomy. At the appropriate period of the experiment, pieces of the intestinal wall were taken using the incisional method - up to 50 cm of the adductor and 30 cm of the efferent sections, respectively, every 10 cm, followed by the application of a cassette suture.

Microscopic sections of the intestinal wall were subjected to histological examination (staining of sections of the small intestine with hematoxylin and eosin), neurohistological examination according to the corresponding instructions for morphological research.

RESULTS AND DISCUSSION

The small intestine after resection for acute strangulation obstruction was enlarged in diameter, swollen, with a dull serous membrane, almost black in color, and the efferent loop was spasmodic. In all cases, pronounced peritoneal phenomena were clinically noted, which characterized the presence of acute diffuse peritonitis of varying severity. Necrosis of the intestinal wall was noted in the strangulated loop of intestine due to massive hemorrhagic infarction. Even with a short duration of the disease (6-9 hours), when stained with hematoxylin and eosin, edema, lymphostasis, hemorrhagic tissue infarction with diffuse purulent inflammation of the mucous membrane and areas of bacterial accumulation were observed in the intestinal wall. In the dilated vessels of the submucosa there is blood stasis and minor hemorrhages.

In the areas closest to the necrotic zone (5-10 cm) of the afferent loop of the small intestine, the blood vessels are filled with blood. The intestinal wall is in a state of edema. Significant changes are observed in the mucous membrane. The epithelium of the intestinal villi is separated from the compacted stroma of the villi along the entire length by edematous fluid. The boundaries between columnar absorptive enterocytes are practically indistinguishable; their nuclei are often displaced in the apical direction. The tops of many villi are “naked”, their epithelium is desquamated, which corresponds to the III-IV severity of morphological damage to the epithelial lining of the villi of the small intestine. Necrobiotic changes are observed in the enterocytes of the crypts. The activity of the enzymes succinate dehydrogenase and acid phosphatase could not be determined. When impregnated with silver nitrate according to Bielschowsky-Gross, nerve cells in the ganglia of the myenteric plexus are not detected. Only their contours and a small number of degenerating nerve fibers are determined.





In areas taken at the border of resection of the small intestine within the limits of viable tissue (40 cm), swelling of all membranes of the intestinal wall is observed. Microvascular vessels are in a state of stasis, leukodiapedesis is common. The loose connective tissue of the stroma of the intestinal villi is compacted and infiltrated with polymorphocellular elements. There are signs of subepithelial edema everywhere in the villi. Columnar epithelial cells are swollen, their height is reduced, the cytoplasm is turbid, the nuclei are displaced in the apical direction. The number of goblet cells increases. In these same areas, the nerve elements of the myenteric nerve plexus are argentophilic, and the nuclei of neurons are not always visualized. The processes of neurons thicken, and additional short spiny projections appear on their bodies.

The functional properties of enterocytes are impaired. The activity of succinate dehydrogenase sharply decreases, which in the control is localized in the form of dark blue granules in the apical and basal poles of enterocytes. At a distance of 40 cm from the strangulation furrow, the number of granules that indicate enzyme activity is insignificant; only pale fine granules are detected. The localization and severity of enterocyte staining when determining acid phosphatase changed with an increase in the amount of precipitated reaction product compared to the control.

When studying the intestinal wall, which was subjected to resection due to thrombosis of the branches of the superior mesenteric artery and vein, we identified severe ischemic and inflammatory changes in its afferent loop at a distance of 50 cm from the boundaries of necrosis. At a distance of 10 cm orally from the necrotically changed area of the intestine, swelling of all the membranes of the organ wall is observed. In the mucous membrane it is manifested by a significant expansion of the subepithelial spaces. The intestinal villi are of unequal length, have bare tips, and in some of them the enterocytes are desquamated from the tip to the base of the villi. Enterocytes are swollen, their cytoplasm is cloudy, nuclei of different sizes are dislocated towards the apical pole, karyopyknosis of individual nuclei is detected. The borders of enterocytes do not differ. The degree of damage to the mucous membrane is mainly III-IV, in some places areas are characterized by V degree of damage, where disintegration of the lamina propria of the mucous membrane with hemorrhages and ulceration is observed. The crypts are shortened and focally destroyed. In the stroma of the villi there is polymorphic cell infiltration.






The nerve elements of the myenteric nerve plexus are weakly impregnated, have blurred contours, and their nuclei are rarely identified. Only individual neurons have roughened, deformed processes.

At a distance of 40 cm of the afferent loop in the crypts, the cells are preserved, and one can hope for the regeneration of the epithelial layer of the intestine. The activity of succinate dehydrogenase in enterocytes is sharply reduced. When testing for acid phosphatase, enterocytes are stained unevenly. Neurons of the myenteric nerve plexus are hyperchromic. More often, long-axonal Dogel type I neurocytes are detected, in which the short processes thicken and contain flask-type influxes of cytoplasm. The stroma of the nerve ganglia becomes clear. Only at a distance of 50-55 cm above the necrosis zone does the histological structure of the intestine stabilize while maintaining slight edema and inflammatory lymphocytic infiltration (I-II degree of damage). Compared to the previous site, enzyme activity is higher, but does not reach normal levels. In the efferent loop, the most pronounced pathohistological abnormalities are observed at a distance of 30 cm aboral to the necrosis zone. At a distance of 40 cm, moderate swelling and lymphoplasmacytic infiltration (I-II degrees of damage) are observed in the mucous membrane.

For adhesive intestinal obstruction, the volume of resection varied from 20 cm to the entire ileum. The section of intestine that was subjected to resection was usually deformed, narrowed in diameter, and had a thickened wall. The adhesions consisted of dense connective tissue adherent to the serous membrane of the intestinal wall. The muscular layer is moderately hypertrophied. Significant changes were found in the mucous membrane - swelling of the villous stroma, swelling of enterocytes, decreased activity of succinate dehydrogenase, which indicated degree I-II damage. Neurons are hyperemic, with thickened, rough processes.

Thus, morphofunctional studies of the wall of the small intestine within the limits of its resection for small intestinal obstruction showed a variety of changes in the vessels, nerve formations and mucous membrane, which differ during strangulation and obturation.

In conditions of acute obstruction of the strangulation type, with circulatory disorders, ischemic changes prevail, which are complicated by inflammatory phenomena. In obstructive intestinal obstruction, pathohistological signs were less pronounced, which indicates that ischemia significantly worsens strangulation.





Changes in enterocytes may indicate damage to the intestinal mucosa in combination with damage to its neural structures. In the dynamics of restoration of the structure and function of the mucous membrane after the elimination of small intestinal obstruction, these moments may cause insufficiency of intestinal anastomoses due to a biased assessment of the state of viability of the intestinal wall.

After the resumption of patency of the small intestine using the generally accepted treatment regimen, structural changes in the intestinal wall were manifested by the regeneration of the epithelium of partially structured villi. Diapedetic hemorrhages in the submucosal and muscular layers, focal necrosis, and desquamation of the mucous membrane spreading to its deep layers were detected.

Thus, under conditions of drug correction of small intestinal ischemia with reamberin, activation of regenerative processes in the mucous membrane of the suprastenotic part of the small intestine was observed, which ensures the functional restoration of resorptive and vascular processes in the intestinal wall.

conclusions


CONCLUSION

Histopathological changes in the afferent and efferent loops of the intestine in humans and experimental animals at different distances from the necrotic zone have pronounced features. Within the generally accepted resection limits - 40 cm of the adductor and 20 cm of the efferent loop - they differ depending on the type of obstruction.

A comprehensive study of the wall of a remote section of the small intestine using histological, histochemical and impregnation methods during strangulation showed the problematic nature of its resection within generally accepted boundaries due to its insufficient viability.

The use of reamberin solution in the complex surgical treatment of acute intestinal obstruction, depending on the time of restoration of patency, contributed to the reduction of pathological morphofunctional changes with the restoration of the barrier, motor evacuation, secretory and absorption functions of the small intestine, which makes it possible to introduce the proposed pathogenetically based method of complex treatment of acute small intestinal obstruction into clinical practice.

Literatures





ISSN (E): 2181-4570 ResearchBib Impact Factor: 6,4 / 2023 SJIF(2023)-3,778 Volume-1, issue-10

1. Davlatov, S., Kan, S., Abduraimov, Z., & Usarov, S. (2017). FACTOR ANALYSIS METHOD OF SELECTION OF PLASTICS ABDOMINAL WALL PATIENTS WITH VENTRAL HERNIAS. *European Science*, (2), 84-88.
2. Sharipovna, N. F., Eshmamatovna, D. N., Norbekovich, T. B., Oblakulovich, K. S., & Abduraimovich, A. Z. (2021). BIOLOGICAL ROLE OF MICROELEMENTS AND THEIR CONTENT IN EPIDERMAL FORMATIONS. *European Journal of Molecular and Clinical Medicine*, 8(2), 1675-1687.
3. ДАВОСИНИНГ, О. К. Г. В. Ч., & КОНЦЕПЦИЯСИ, З. (2016). СОВРЕМЕННАЯ КОНЦЕПЦИЯ ЛЕЧЕНИЯ БОЛЬНЫХ С ГИГАНТСКИМИ ПОСЛЕОПЕРАЦИОННЫМИ ВЕНТРАЛЬНЫМИ ГРЫЖАМИ. *Проблемы биологии и медицины*, (1), 86.
4. Shukurullaevich, A. D., Amirovich, M. B., Sulaymonovich, D. S., & Abduraimovich, A. Z. (2021). Tensioned hernioplasty and abdominoplasty in patients with morbid obesity. *Вестник науки и образования*, (3-2 (106)), 88-98.
5. Давлатов, С. С., Кан, С. А., Абдураимов, З. А., & Усаров, Ш. Н. (2017). Пути устранения послеоперационных осложнений при герниопластике вентральных грыж у больных сопутствующим ожирением. *Медицинский журнал Узбекистана*, (3), 28-33.
6. Erdanovich, R. K., Sulaimanovich, D. S., Shukurillaevich, A. D., & Abduraimovich, A. Z. (2022). Criteria For Selecting Surgical Treatment Of Patients With Ventral Hernias And Obesity. *Periodica Journal of Modern Philosophy, Social Sciences and Humanities*, 3, 40-46.
7. Ilhomovna, K. M., Khidirov, Z. E., & Abduraimovich, A. Z. ANATOMICAL FEATURES OF THE NOSE AND NASAL CAVITY.
8. Khidirov, Z. E., & Zafarjon, A. (2023). Views on " Postcholecystectomy Syndrome". *Central Asian Journal of Medical and Natural Science*, 4(3), 200-206.
9. Zafarjon, A., & Khidirov, Z. E. (2023). MAIN CAUSES, DIAGNOSIS, AND EFFECTIVE TREATMENT OF POSTCHOLECYSTECTOMY SYNDROME. *World Bulletin of Public Health*, 21, 223-228.
10. Хамракулова, Н. О., & Абдураимов, З. А. (2022). СРАВНИТЕЛЬНАЯ ОЦЕНКА ЭФФЕКТИВНОСТИ КОНСЕРВАТИВНОГО И ХИРУРГИЧЕСКОГО МЕТОДОВ ЛЕЧЕНИЯ БОЛЬНЫХ С ХРОНИЧЕСКИМ ГНОЙНЫМ СРЕДНИМ





ОТИТОМ. ЖУРНАЛ СТОМАТОЛОГИИ И КРАНИОФАЦИАЛЬНЫХ ИССЛЕДОВАНИЙ, 3(3).

11. Курбанова, Л. М., Хидиров, З. Э., & Абдураимов, З. А. (2021). КЛИНИКО-ЭПИДЕМИОЛОГИЧЕСКИЕ ОСОБЕННОСТИ ТЕЧЕНИЯ БРУЦЕЛЛЁЗА В ВОЗРАСТНОМ АСПЕКТЕ В САМАРКАНДСКОЙ ОБЛАСТИ. *Достижения науки и образования*, (1 (73)), 61-68.

12. Абдураимов, З. А., Коржавов, Ш. О., Шамсиева, Р. А., Шавкатуллаева, Д. Г., Хасанова, М. Б., & Негматов, Х. И. (2013). ПУТИ УСТРАНЕНИЯ ПОСЛЕОПЕРАЦИОННЫХ ОСЛОЖНЕНИЙ ПРИ ПЛАСТИКЕ ВЕНТРАЛЬНЫХ ГРЫЖ У БОЛЬНЫХ С СОПУТСТВУЮЩИМ ОЖИРЕНИЕМ. *SCIENCE AND WORLD*, 50.

13. Давлатов, С. С., Хидиров, З. Э., & Насимов, А. М. (2017). Дифференцированный подход к лечению больных с синдромом Мириizzi. *Academy*, (2 (17)), 95-98.

14. Абдурахманов, Д., Рахманов, К., & Давлатов, С. (2021). Тактико-технические аспекты хирургических вмешательств при грыжах живота и сочетанной абдоминальной патологии. *Журнал гепато-гастроэнтерологических исследований*, 2(3), 11-16.

15. Davlatov, S. S., Khidirov, Z. E., & Nasimov, A. M. (2017). Differentiated approach to the treatment of patients with Mirizzi syndrome. *Academy*, 2, 17.

16. Shukurullaevich, A. D., Erdanovich, R. K., Sulaymonovich, D. S., & Erkinovich, N. Z. (2021). Quality of life of patients before and after surgical treatment of diffuse toxic goiter. *Вестник науки и образования*, (3-2 (106)), 80-87.

17. Давлатов, С. С., Хидиров, З. Э., & Насимов, А. М. (2017). Выбор дифференцированной тактики лечения больных с синдромом Мириizzi. *Западские чтения*, 62-65.

18. Мустафоев, З. М., Бахронов, Ж. Ж., & Хидиров, З. Э. (2022). Яллиғланишга қарши дори воситалари полипрагмазиясида буйрак нефронларида рўй берадиган морфометрик ўзгаришлар. *Биология ва тиббиёт муаммолари.- Самарқанд–2022*, 3, 177-181.

19. Davlatov, S. S., Khidirov, Z. E., & Nasimov, A. M. (2017). Differentirovannuyu podkhod k lecheniyu bolnykh s sindromom Mirizzi [Differentiated approach to the treatment of patients with Mirizzi syndrome].





ISSN (E): 2181-4570 ResearchBib Impact Factor: 6,4 / 2023 SJIF(2023)-3,778 Volume-1, issue-10

20. Хусанов, Э. У., Коржавов, Ш. О., & Сулейманов, Р. И. (2019). Исследование экскреции лактата кожей в зависимости от различных факторов. *Re-health journal*, (2), 72-75.
21. Ilhomovna, K. M., Khidirov, Z. E., & Abduraimovich, A. Z. ANATOMICAL FEATURES OF THE NOSE AND NASAL CAVITY.
22. Erdanovich, R. K., Sulaimanovich, D. S., Shukurillaevich, A. D., & Erkinovich, K. Z. (2022). Tactical And Technical Aspects of Surgical Interventions for Ventral Hernias and Obesity. *Periodica Journal of Modern Philosophy, Social Sciences and Humanities*, 3, 26-39.
23. Erkinovich, X. Z., Murodullavena, K. L., Mamadievich, R. Z., Mamirkulovich, M. Z., Xidirovna, L. Z., Oblakulovich, K. S., & Axmadjonovich, S. S. (2021). Improving the Surgical Treatment of Patients with a Biliary Disease Complicated by Mirizzy Syndrome. *Annals of the Romanian Society for Cell Biology*, 25(6), 14697-14702.

